




Club's Anatomy



NERVOUS SYSTEM

Medical Club Team

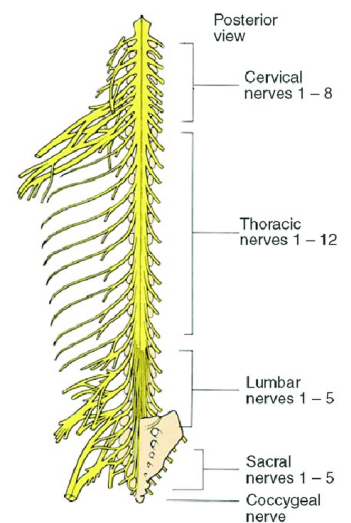
Spinal nerves

Peripheral nerves (nerves of the peripheral nervous system) is a collective term for the cranial and spinal nerves. Each peripheral nerve consists of parallel bundles of **nerve fibers** and their associated neuroglial cells wrapped in several layers of connective tissue. These nerve fibers may be **efferent** or **afferent** axons, may be myelinated or nonmyelinated.

Note: cranial nerves will be discussed when we talk about the brain.

Remember: nerves are bundles of axons (no dendrites) and their associated neuroglial cells wrapped in layers of connective tissue. Nerves are arranged in a way which is identical to the arrangement of skeletal muscles. Please refer to the previous sheet to revise this topic. I want to emphasize on something that was mentioned in the previous lecture which is: although the majority of the axons in the peripheral nerve are myelinated, there are some which are not myelinated.

Spinal nerves: spinal nerves are mixed nerves that send motor and sensory signals between the CNS and the body. They connect the CNS to sensory receptors, muscles, and glands in all parts of the body. There are 31 pairs of symmetrically arranged spinal nerves (8 cervical pairs, 12 thoracic pairs, 5 lumbar pairs, 5 sacral pairs, and 1 coccygeal pair). The spinal cord appears to be segmented because the 31 pairs of spinal nerves emerge at regular intervals from the spinal cord through intervertebral foramina (each pair of spinal nerves is said to arise from a spinal segment). In other words, the spinal cord is formed of 8 cervical, 12 thoracic, 5 lumbar, 5 sacral and 1 coccygeal **spinal segments**. Each spinal segment has right and left **spinal nerves** (each spinal segment has one pair; one on the left and on the right). Actually, within the spinal cord there is no obvious segmentation but, to make it easier, the naming of spinal nerves is based on the segment in which they are located.



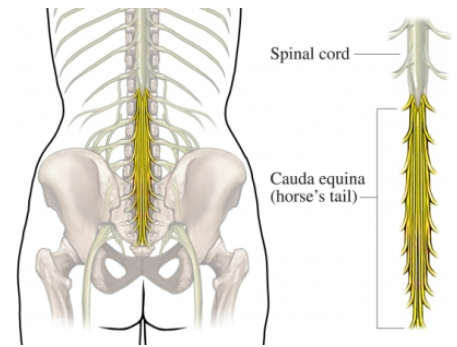
Note: all spinal nerves—**except the first pair**—emerge from the spinal column through an opening between vertebrae, called an intervertebral foramen. The first cervical pair emerges between the atlas (first cervical vertebra) and the occipital bone.

In early embryonic life, the cord is as long as the vertebral canal, but as development proceeds, it lags behind the growth of the vertebral column. Consequently, the cord segments move upward in relation to the vertebrae and these segments will not be aligned with their corresponding vertebrae, and as we proceed from cervical to sacral levels, the distance between the spinal segments and their corresponding vertebrae become longer. Because of that, the nerve roots, which are originally horizontal, will assume an increasingly oblique direction from above downward (descend at an angle) as they proceed to their respective foramina before emerging from the vertebral column, especially the lumbar, sacral, and coccygeal nerves.

Note: segmentation of the spinal cord (spinal segments) corresponds to the intrauterine (embryo) period in which, as we said, the spinal cord occupies the entire vertebral canal. For this reason in adulthood, where the vertebral column is longer than the cord, each spinal cord segment is located higher than its corresponding vertebra.

In the adult, except in the upper cervical region, the cord segments lie at varying distances above the corresponding vertebrae. Approximately, the lower cervical spinal segments are one level above their corresponding vertebrae, the lower thoracic spinal segments two levels above and the lumbar spinal segments three levels above their corresponding vertebrae. Regarding this distance, Spinal nerves, however, exit the vertebral column at their correspondingly numbered vertebrae. So in order for the more distal spinal nerves to exit they must first descend through the vertebral canal.

The nerve roots attached to the lower part of the cord (lumbar and sacral) descend to their points of exit as the cauda equina, named for their resemblance to the tail of a horse. And that's how the cauda equina is formed.



Illustrative example: the lumbar, sacral, and coccygeal segments of the cord are crowded together and occupy the space approximately opposite the ninth thoracic to the first lumbar vertebrae. These alterations of the cord segments relative to the vertebral segments explain why the cervical enlargement (C4 to T2) lies approximately opposite the corresponding vertebrae, whereas the lumbar enlargement (L3 to S3) lies opposite the last three thoracic vertebrae.

Cervical spinal nerves exit through the intervertebral foramina directly above their corresponding vertebrae, whilst thoracic, lumbar and sacral spinal nerves exit directly below.

Illustration: the peripheral nerves emerge through the intervertebral foramina. At thoracic, lumbar, sacral and coccygeal levels, the numbered nerve exits the vertebral canal by passing below the pedicle of the corresponding vertebra, e.g. L4 nerve exits the intervertebral foramen between L4 and L5. However, in the cervical region, nerves C1–7 pass above their corresponding vertebrae. C1 leaves the vertebral canal between the occipital bone and atlas, and hence is often termed the suboccipital nerve. The last pair of cervical nerves does not have a correspondingly numbered vertebra and C8 passes between the seventh cervical and first thoracic vertebrae.

Organization of Spinal Nerves:

The design of a spinal nerve is like that of a tree. Beneath the ground, tiny rootlets converge to form large tree roots. These large roots come together at the surface to form the trunk, which then divides into numerous large branches that fork into smaller and smaller branches. Spinal nerves follow the same pattern and use much of the same terminology.

The spinal nerves arise from the spinal cord as a series of small rootlets. The two types of rootlets are anterior (ventral) rootlets and posterior (dorsal) rootlets. Spinal nerves are attached to the cord in linear series by anterior and posterior nerve rootlets, or filaments, which coalesce/unite to form the nerve roots. Each posterior spinal nerve root possesses an oval enlargement, the spinal (sensory) ganglion.

The nerve filaments, or rootlets, are attached to the cord along its anterolateral and posterolateral sulci by 2-3 irregular rows.

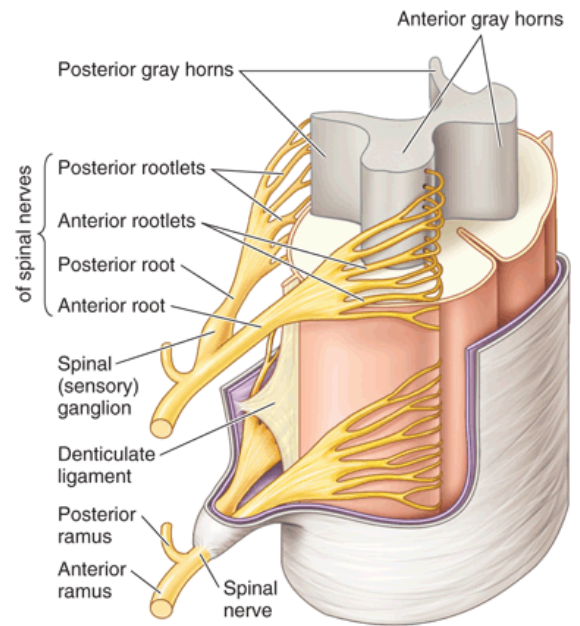
Anterior Rootlets:

The anterior (ventral) filaments emerge in two or three irregular rows. They are composed predominantly of efferent fibres, which are the axons of multipolar motor neurons arising from cell bodies in the anterior columns, or horns, of gray matter, and they carry motor impulses to the voluntary muscles. In the thoracic and upper lumbar regions, the filaments also contain preganglionic sympathetic (autonomic) fibres, which are the axons of lateral columnar cells (lateral gray horn). So in general, the axons of the anterior rootlets transmit action potentials to the muscles and glands of the body.

Posterior Rootlets:

The posterior (dorsal) filaments are attached along a shallow groove, the posterolateral sulcus, and are prolongations (collections of the central processes) of pseudounipolar nerve cells located in the dorsal root ganglia (not in the spinal cord) of the related dorsal nerve roots. The lateral cell processes pass on in spinal nerves and their branches to peripheral receptors, and they convey afferent impulses back to the spinal cord from somatic, visceral, and vascular sources. After that, they enter the spinal cord to the dorsal/sensory horn. From there, the signals ascend in ascending tracts. In other words, these neurons transmit action potentials from peripheral receptor organs to the central nervous system.

Extra note: Rootlets join to form the anterior roots (from 6 to 8 anterior rootlets) and posterior roots (from 8 to 10 posterior rootlets).



Each series of anterior rootlets converges to form larger anterior (ventral) roots. Likewise, each series of posterior rootlets converges to form larger posterior (dorsal) roots. Each posterior root has a swelling, the posterior (dorsal) root ganglion, which contains the cell bodies of sensory neurons (the ventral root has no ganglia as the cell bodies are located in the gray matter of the spinal cord). The anterior and posterior roots on each side of the spinal cord correspond to one developmental segment or level of the body (body segmentation is an embryological topic that you are not required to know). As the sensory posterior root and motor anterior root project laterally from the spinal cord, they converge, at the intervertebral foramen, to form a mixed nerve called the spinal nerve trunk. (A mixed nerve contains both motor and sensory axons). The spinal nerve trunk runs for a short distance before branching into two large branches (ventral and dorsal rami) and a variable series of smaller branches.

Question: Why is the spinal nerve short?

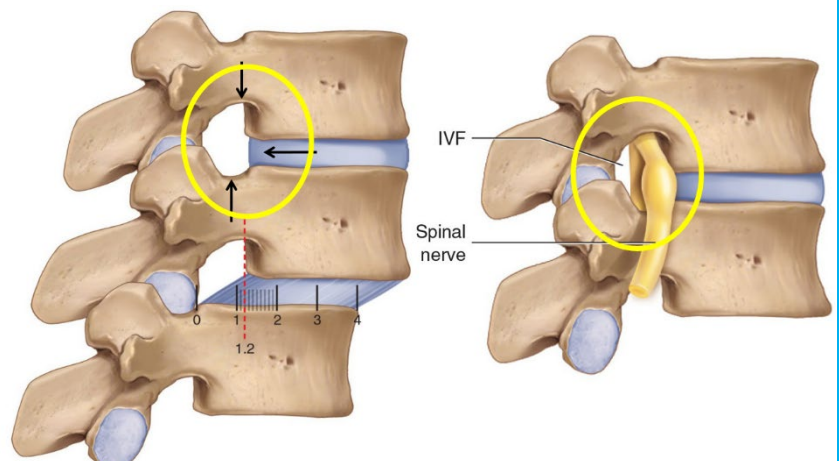
Answer: because it branches shortly after formation into 2 large rami.

Notes:

- **Spinal nerves are united ventral and dorsal spinal roots**, attached in series to the sides of the spinal cord. Immediately beyond the spinal ganglion, the anterior and posterior nerve roots unite to form the trunk of spinal nerve which emerges through the intervertebral foramen. The term spinal nerve strictly applies only to the short segment after union of the roots and before branching occurs.
- The spinal nerve (and dorsal root ganglia) are located in the intervertebral foramen.
- Each dorsal root bears a spinal, sensory ganglion (dorsal root ganglion).

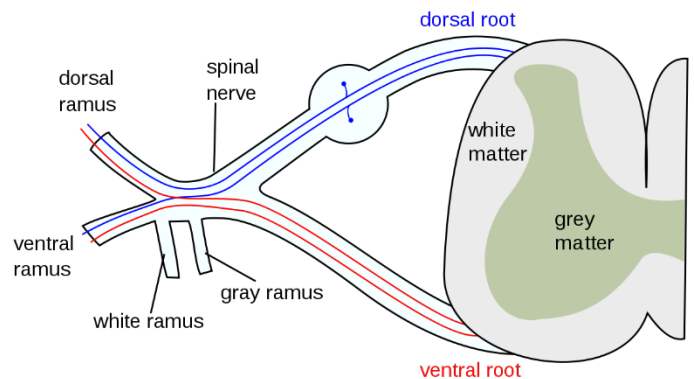
Vertebral foramen:

The intervertebral foramen is made by a notch in the pedicles of the vertebrae above and a notch on the superior surface of the vertebra below plus the intervertebral disc between these 2 vertebrae. We see in this foramen the short spinal nerve.



Branches of Spinal Nerves:

The roots arise from the spinal cord, and unite at the intervertebral foramina (Immediately distal to the spinal ganglia), forming a single spinal nerve. These very soon divide into dorsal and ventral rami, both of which receive fibres from both roots. At all levels above the sacral, this division occurs within the intervertebral foramen. Division of the sacral spinal nerves occurs within the sacral vertebral canal, and the dorsal and ventral rami exit separately through posterior and anterior sacral foramina at each level.



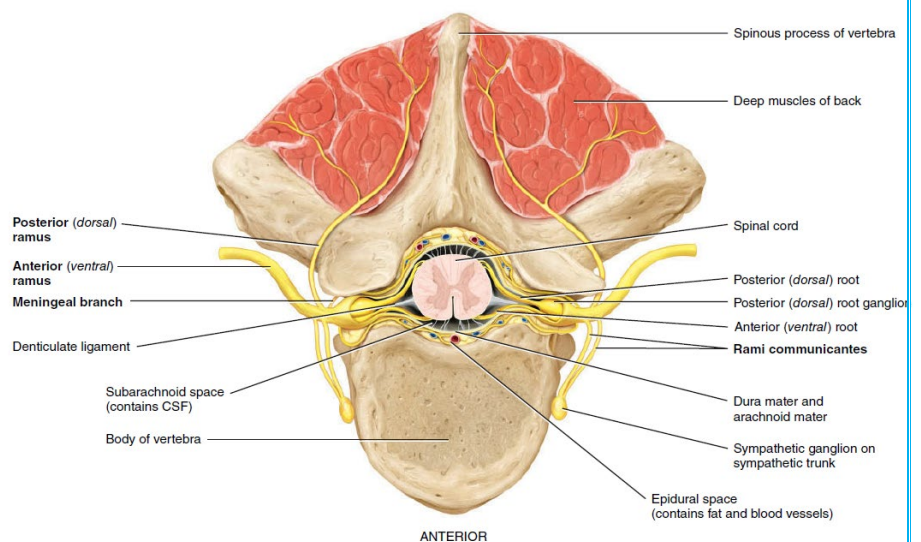
Each large spinal nerve branch, named a ramus plural is rami), follows a specific course to different peripheral regions. The two largest branches, the anterior (ventral) ramus and posterior (dorsal) ramus, are **somatic** branches that run in the musculoskeletal wall of the body.

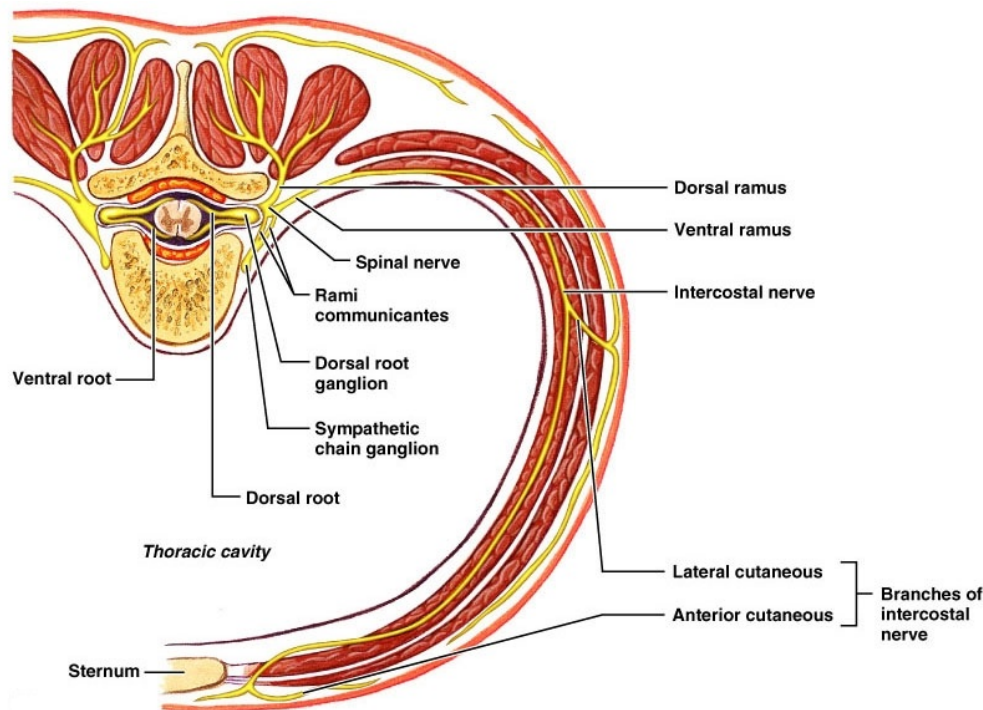
- The posterior (dorsal) ramus serves the deep muscles and skin of the posterior surface of the trunk. In other words, sensory → skin of the back / motor → muscles of the back.
- The anterior (ventral) ramus serves the muscles and skin of the upper and lower limbs and the muscles and skin of the lateral and anterior regions of the trunk. In general, ventral rami are larger than the dorsal rami. **Anterior rami give anterior and lateral cutaneous branches.**

Note: thoracic ventral rami run independently and retain a largely segmental distribution. Cervical, lumbar and sacral ventral rami connect near their origins to form plexuses. Dorsal rami do not join these plexuses (plexuses will be discussed below).

Smaller **visceral** branches, such as the meningeal branch and the communicating rami, form the autonomic pathways to smooth muscle and glandular tissue. The meningeal branch reenters the vertebral canal through the intervertebral foramen and supplies the vertebrae, vertebral ligaments, blood vessels of the spinal cord, and meninges. The communicating rami or rami communicantes are components of the autonomic nervous system and will be discussed later.

Illustration: at or distal to its origin, each ventral ramus gives off recurrent meningeal branches and receives a grey ramus communicans from the corresponding sympathetic ganglion. The thoracic and first and second lumbar ventral rami each contribute a white ramus communicans to the corresponding sympathetic ganglia. The second, third and fourth sacral nerves also supply visceral branches, unconnected with sympathetic ganglia, which carry a parasympathetic outflow direct to the pelvic plexuses.





After discussing the spinal nerves, we can conclude that the contents of spinal nerves are motor, sensory, and sympathetic. Somatic sensory fibers will receive information from sensory receptors in the skin and transmitted to the spinal cord. Each spinal nerve will supply a specific area of skin. This area is called dermatome. The next spinal nerve will supply another specific area of skin (another dermatome) and so on. The nerve roots supplying neighboring dermatomes overlap. Thus, sectioning or dysfunction of a single dorsal root produces hypoesthesia (diminished sensation), not anesthesia (total loss of sensation) in the region supplied predominantly by that dermatome, as shown in the figure. Dermatomal anesthesia requires damage to at least three dorsal roots: the central dorsal root and the roots above and below it (the doctor said if we cut a spinal nerve then we will lose sensation of the dermatome that it supplies).

Somatic motor fibers will innervate skeletal muscles. A group of muscles primarily innervated by the motor fibres of a single nerve root is known as a myotome. If the spinal nerve that supplies a myotome is damaged, paralysis of those muscles will happen.

Sympathetic (autonomic) fibers will supply blood vessels and glands.

Extra illustration, just for the sake of knowledge (don't memorize any additional notes mentioned below).

Functional components of spinal nerves

A typical spinal nerve contains somatic efferent fibres and somatic and visceral afferent fibres. Some, but not all, spinal nerves also contain preganglionic autonomic fibres.

- **Somatic components**

Somatic efferent fibres innervate skeletal muscles and are axons of α , β and γ neurones in the spinal ventral grey column. Somatic afferent fibres convey impulses into the central nervous system from receptors in the skin, subcutaneous tissue, muscles, tendons, fasciae and joints; they are peripheral processes of unipolar neurones in the spinal ganglia.

- **Visceral components**

Preganglionic visceral efferent sympathetic fibres are axons of neurones in the spinal intermediolateral grey column throughout the thoracic and upper two or three lumbar segments; they join the sympathetic trunk via corresponding white rami communicantes and synapse with postganglionic neurones that are distributed to smooth muscle, myocardium or exocrine glands. The preganglionic visceral efferent parasympathetic fibres are axons of neurones in the spinal lateral grey column of the second to fourth sacral segments; they leave the ventral rami of corresponding sacral nerves and synapse in pelvic ganglia. The postganglionic axons are distributed mainly to smooth muscle or glands in the walls of the pelvic viscera. Visceral afferent fibres have cell bodies in the spinal ganglia. Their peripheral processes pass through white rami communicantes and, without synapsing, through one or more sympathetic ganglia to end in the walls of the viscera. Some visceral afferent fibres may enter the spinal cord in the ventral roots.

Central processes of ganglionic unipolar neurones enter the spinal cord by dorsal roots and synapse on somatic or sympathetic efferent neurones, usually through interneurones, completing reflex paths. Alternatively, they may synapse with other neurones in the spinal or brainstem grey matter that give origin to a variety of ascending tracts.

Clinical correlations:

Osteophytes:

Osteophytes are bony lumps (bone spurs) that grow on the bones of the spine or around the joints.

With old age, especially if the person is heavy weight, the vertebrae will develop called osteophytes and if an osteophyte grows into the intervertebral foramen then it's going to put pressure on the spinal cord leading to pain.

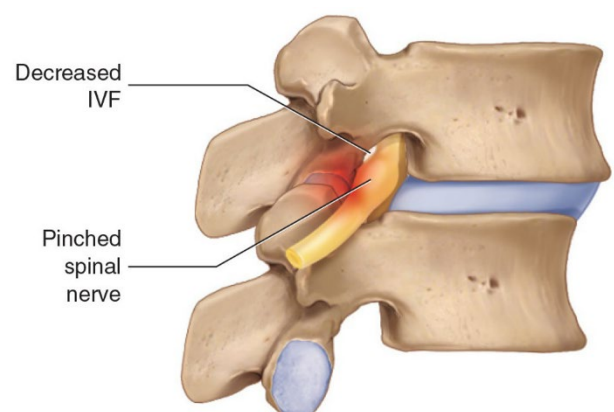
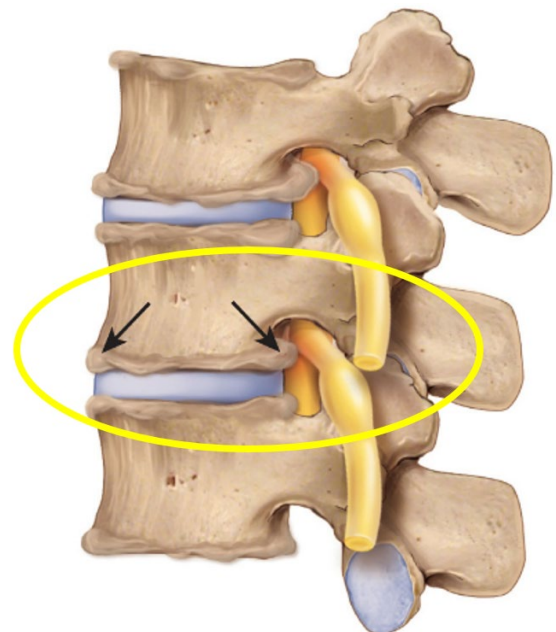
Osteophytes often form next to joints affected by osteoarthritis, a condition that causes joints to become painful and stiff.

Notes:

- The lumbar spine has the highest prevalence of vertebral osteophytes.
- Increase in body mass and heavy physical activity, mainly in males, may cause intervertebral disc degeneration followed by osteophytes formation.

Disc herniation:

A herniated disc is a condition affecting the spine in which the annulus fibrosus is damaged enabling the nucleus pulposus (which is normally located within the centre of the disc) to herniate. This can compress the nerves or spinal cord causing pain and spinal cord dysfunction. Disc herniation can occur in any disc in the spine, but



the two most common forms are lumbar disc herniation and cervical disc herniation. The lumbar being the most common, causing low back pain and often leg pain as well, in which case it is commonly referred to as sciatica.

With age, the nucleus pulposus of the disk dehydrates, placing more stress on the annulus fibrosus (outer lining). Tears or ruptures in the annulus may permit a sudden herniation of the nucleus—a ruptured disc. Alternatively, chronic annular bulging or nuclear herniation may lead to the formation of extensive bony spurs (osteophytes), typically located along the anterior portion of the disk interspace or posteriorly within the nerve root foramen. Osteophytes or ruptured disks produce symptoms **only if they compress the spinal cord or nerve roots against posteriorly located structures.**

Question: why would the herniated disc compress the spinal cord?

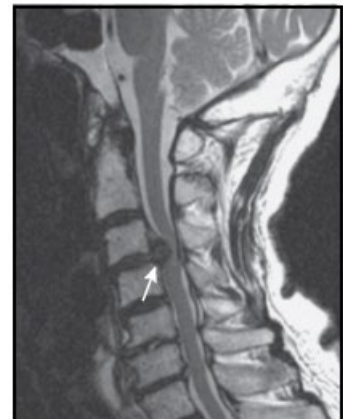Answer: The intervertebral foramen is a confine space made by bones and intervertebral disc and it has the spinal nerve inside it. The space is very confine, so if there is a protrusion of the intervertebral disc then there is a pressure on the spinal nerve

Symptoms depend on the region of the spinal cord that is involved (i.e. along the distribution of the spinal nerve that is affected), below are some of them:

1. Pain; for example:
 - Neck pain
 - Lower back pain
 - Pain in the buttocks, hips or legs if the disc is pressing on the sciatic nerve (sciatica)
2. Numbness or tingling in your shoulders, back, arms, hands, legs or feet.
3. Muscle weakness.

Extra note: MRI is the preferred and most sensitive study to visualize herniated disc.

- This is a sagittal MRI showing disk extrusion at C3-4



Plexuses:

Definition: a nerve plexus is a network of intersecting nerves

Axons from the anterior rami of spinal nerves, except for thoracic nerves T2–T12, do not go directly to the body structures they supply. Instead, they form networks on both the left and right sides of the body by joining with various numbers of axons from anterior rami of adjacent nerves. Such a network of axons is called a plexus (plexus= network). The principal spinal nerve plexuses are the cervical plexus, brachial plexus, lumbar plexus, and sacral plexus. A smaller coccygeal plexus is also present. Emerging from the plexuses are nerves bearing names that often describe the general regions they serve or the course they take. Each of these nerves may in turn have several branches named for the specific structures they innervate.

In this topic we will describe spinal plexuses somatic plexuses which innervate skin and many muscles that's why they have complicated structures. Later we will describe autonomic plexuses, many of which are a part of the enteric nervous system.

Question: why do we have these plexuses?

- Answer: this arrangement permits each skeletal muscle in a limb to be innervated by motor (afferent) fibers from more than one spinal segment -- as a result, an injury to a single spinal segment or spinal motor (ventral) root cannot completely paralyze any limb muscle.

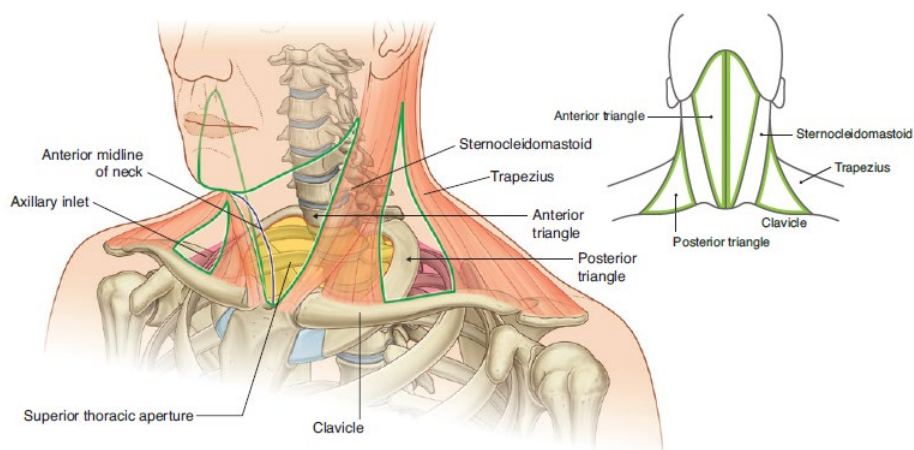
Before we talk about the plexuses, let's first review the intercostal nerves which arise from T2-T12 (the region that doesn't make a plexus)

Intercostal Nerves:

The anterior rami of spinal nerves T2–T12 do not enter into the formation of plexuses and are known as intercostal or thoracic nerves. After leaving its intervertebral foramen, the anterior rami of nerves T2-T12 innervates the intercostal muscles and abdominal muscles. It also supplies skin of the axilla, anterior and lateral chest wall and overlying skin of the abdominal muscles

Cervical Plexus:

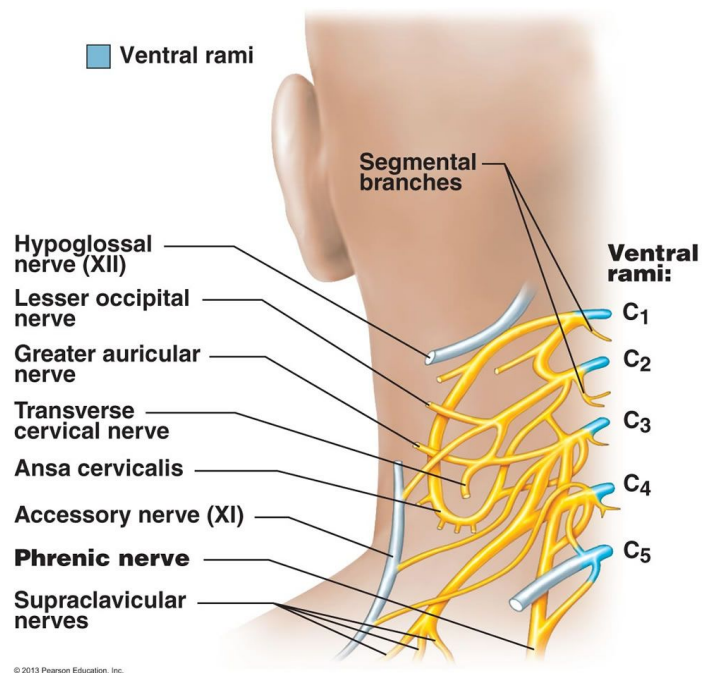
The cervical plexus is formed by the roots (**ventral rami**) of the first four cervical nerves (C1 – C4) with contributions from C5; particularly, the upper part of fifth cervical ventral ramus. There is one plexus on each side of the neck alongside the first four cervical vertebrae. This plexus is located deep within the neck in the posterior triangle of the neck, halfway up the sternocleidomastoid muscle. This figure shows the posterior triangle of the neck.



The cervical plexus supplies the skin and muscles of the head, neck, superior portion of the shoulders and chest, and diaphragm. The phrenic nerves arise from the cervical plexuses and supply motor fibers to the diaphragm. Branches of the cervical plexus also run parallel to two cranial nerves, the accessory (XI) nerve and hypoglossal (XII) nerve (see the figure to the right).

The cervical plexus consists of:

- Muscular (or deep) branches, which are largely motor branches. They innervate the muscles.
- Cutaneous (or superficial) branches, which are sensory branches. They innervate the skin.



Questions:

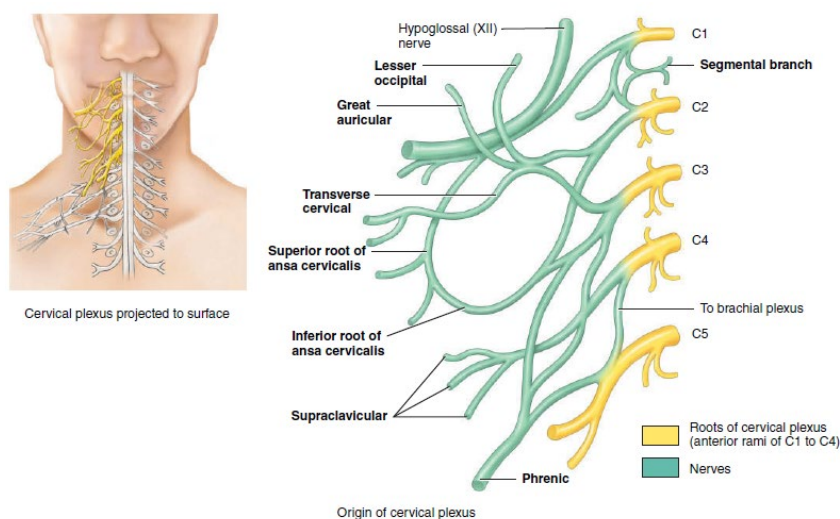
1. Why do we include the fifth cervical nerve (i.e. the upper part of fifth cervical ventral ramus) to the plexus?

Answer: because of its contribution to the formation of one of the branches of the cervical plexus called the phrenic nerve which supplies motor fibers to the diaphragm. It also supplies the diaphragm with sensory innervation.

2. Why this phrenic nerve is very important?

Answer: the phrenic nerve (C3 -C5) is the sole motor supply of the diaphragm and that is one reason why neck injuries are so dangerous -can be lethal- (respiratory arrest = stop breathing).

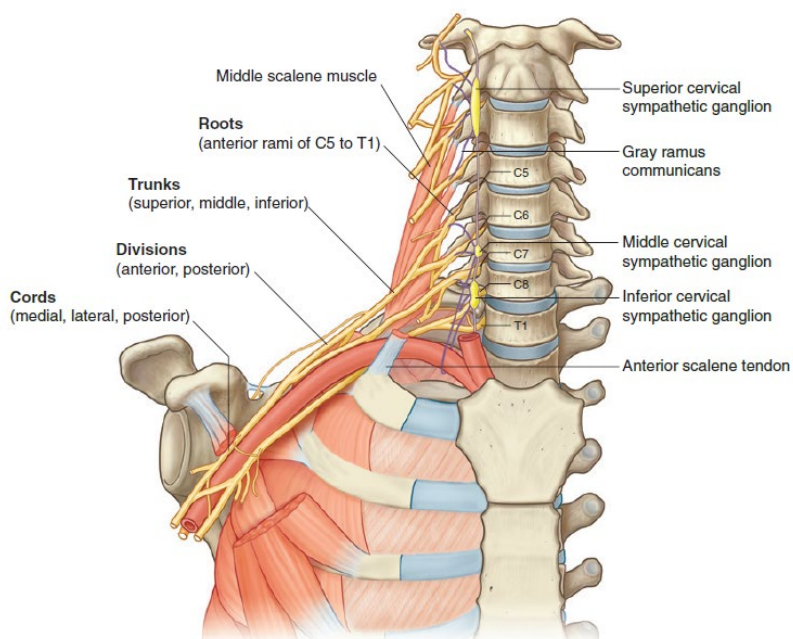
The phrenic nerve is a mixed motor/sensory nerve which originates from the C3-C5 spinal nerves in the neck. The nerve is important for breathing because it provides **exclusive** motor control of the diaphragm, the primary muscle of respiration. *Extra* sensory innervation for the diaphragm is provided by 2 sources; at the central tendinous part is innervated by the phrenic nerves, while the peripheral muscular portions are innervated by 6th to 11th intercostal nerves.



Brachial plexus:

The anterior rami of spinal nerves C5–C8 and T1 form the roots of this plexus. The plexus originates in the neck, passes laterally and inferiorly, on either side of the last four cervical and first thoracic vertebrae, over the first rib posterior to the clavicle, and enters the axilla. The roots lie between the anterior and middle scalene muscles. The brachial plexus provides almost the entire nerve supply of the shoulders and upper limbs.

Extra note: Usually, a small branch from C4 joins the C5 root, and one from T2 joins the T1 root; thus C4 and T2 often provide minor contributions to the plexus.



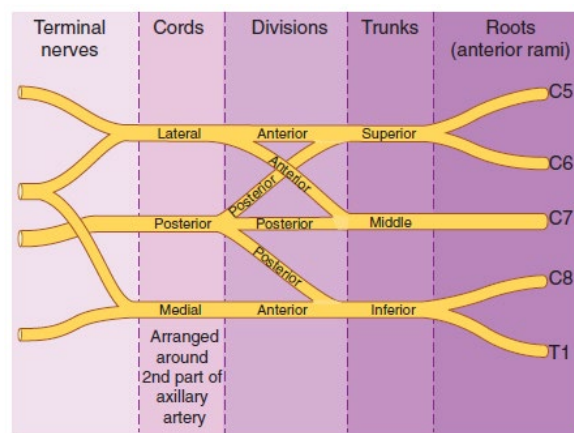
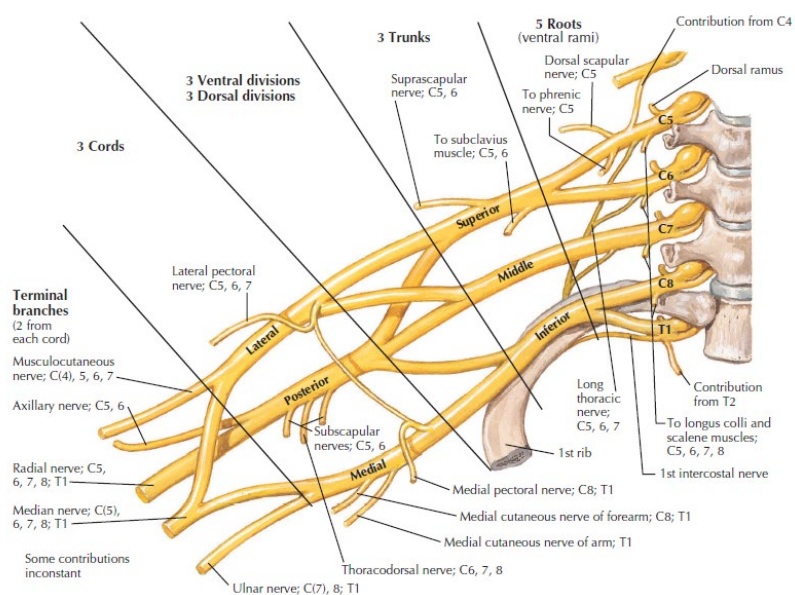
Discussion (the doctor didn't explain it all, but I recommend you to take a look at it and study the figure below it)

As with the cervical and other plexuses, the roots of the brachial plexus are the anterior rami of the spinal nerves. The roots of several spinal nerves unite to form trunks in the inferior part of the neck. These are the superior, middle, and inferior trunks. Posterior to the clavicles, the trunks divide into divisions called the anterior and posterior divisions. In the axillae, the divisions unite to form cords called the lateral, medial, and posterior cords. The cords are named for their relationship to the axillary artery, a large artery that supplies blood to the upper limb. The branches of the brachial plexus form the principal nerves of the brachial plexus.

The brachial plexus provides almost the entire nerve supply of the shoulders and upper limbs. Five large terminal branches arise from the brachial plexus: (focus on the radial, median, and ulnar nerves. The doctor didn't mention the other nerves)

1. The axillary nerve supplies the deltoid and teres minor muscles.
2. The musculocutaneous nerve supplies the anterior muscles of the arm.
3. The radial nerve supplies the muscles on the posterior aspect of the arm and forearm.
4. The median nerve supplies most of the muscles of the anterior forearm (6 1/2 out of 8) and some of the muscles of the hand.
5. The ulnar nerve supplies the anteromedial muscles of the forearm (the other 1 1/2) and most of the muscles of the hand.

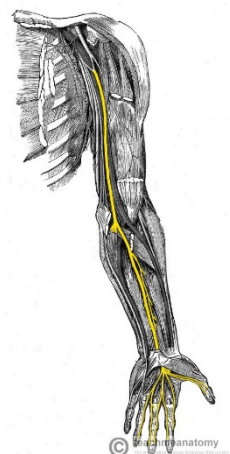
The parts of the brachial plexus, from medial to lateral, are roots, trunks, divisions, and cords. These are shown in the figures below.



We will focus on three major terminal branches which are; the median, radial, and ulnar nerves.

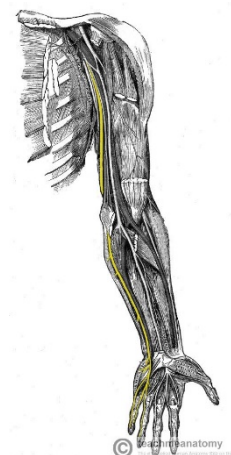
1. **Median nerve:** After originating from the brachial plexus in the axilla, the median nerve descends down the arm, initially lateral to the brachial artery. Halfway down the arm, the nerve crosses over the brachial artery, and becomes situated medially.

The median nerve is the nerve of flexion of the wrist and the hand and it supplies muscles of the anterior compartment of the forearm and some muscles in the hand (lateral palm). It also supplies skin of lateral two-thirds of palm of hand and fingers.



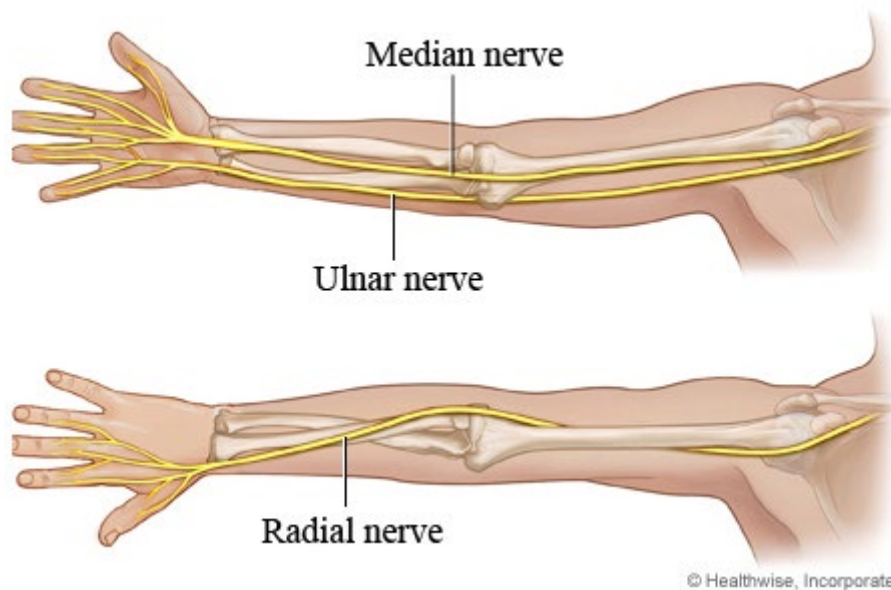
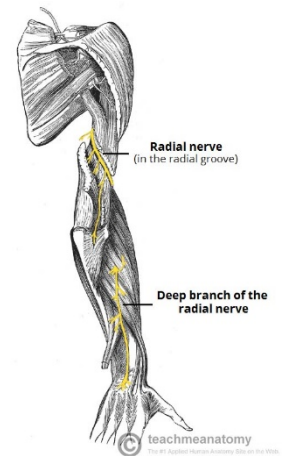
2. **Ulnar nerve:** the ulnar nerve arises from the brachial plexus within the axilla region. After arising from the brachial plexus, it proceeds down the medial aspect of the arm with the brachial artery located lateral. The ulnar nerve passes posterior to the medial epicondyle of the humerus through the ulnar tunnel (small space between the medial epicondyle and olecranon).

The ulnar nerve is going to supply one muscle in the forearm (flexor carpi ulnaris) and most muscles of the hand. It also supplies skin of the medial side of the hand.



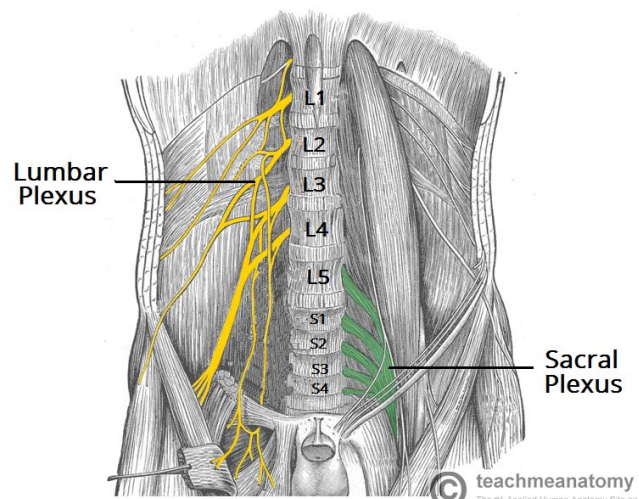
3. **Radial nerve:** it arises in the axilla region. The radial nerve then descends down the arm, travelling in a shallow depression within the surface of the humerus, known as the radial groove. As it descends, the radial nerve wraps around the humerus laterally and travels anterior to the lateral epicondyle of the humerus in order to enter the forearm.

The radial nerve is the nerve of extension (it supplies extensors). Therefore it's going to supply muscles of the posterior compartment of the arm supplying the triceps muscle and the posterior compartment of the forearm. It also supplies skin of posterior arm and forearm and lateral two thirds of dorsum of the hand.



Lumbosacral plexus:

Somatic motor and general sensory innervation of the lower limb is by peripheral nerves emanating from the lumbosacral plexus. This plexus is formed by the anterior rami of the nerves L1-S4 to supply the lower limbs. The lumbosacral plexus can be divided into the lumbar plexus (L1-L4), and the sacral plexus (L4-S4). Clinical signs (such as pain, pins-and-needles sensations, paraesthesia, and fascicular muscle twitching) resulting from any disorder affecting these spinal nerves (e.g., herniated intervertebral disc in the lumbar region) appear in the lower limb.



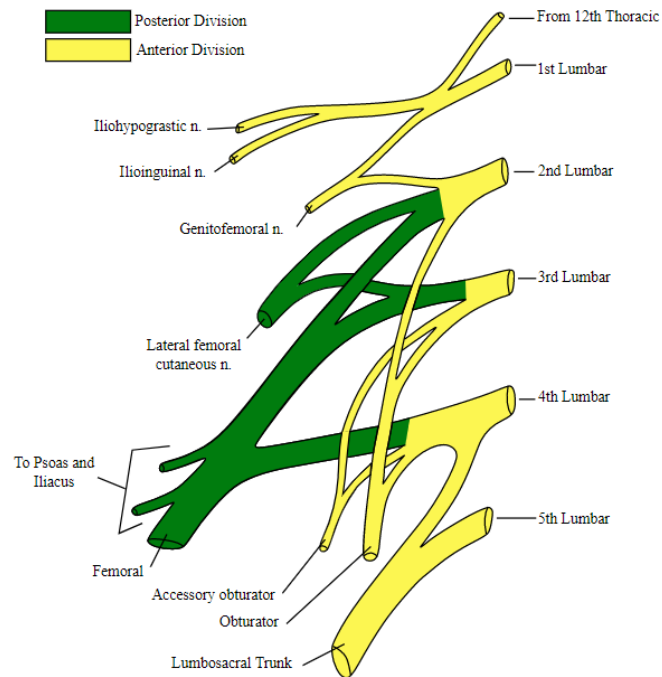
Lumbar Plexus:

The anterior rami of spinal nerves L1–L4 form the roots of the lumbar plexus. It also receives a contribution from the T12 (subcostal) nerve.

Unlike the brachial plexus, the intricate intermingling of fibres is minimal in the lumbar plexus. On either side of the first four lumbar vertebrae, the lumbar plexus passes obliquely outward,

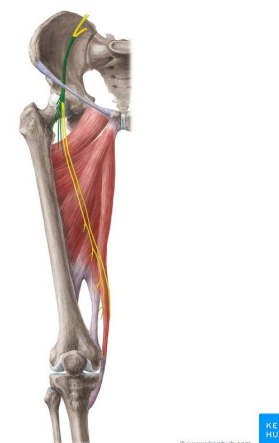
between the superficial and deep heads of the psoas major muscle and anterior to the quadratus lumborum muscle (this note is from the book). Between the heads of the psoas major, the roots of the lumbar plexus split into anterior and posterior divisions, which then give rise to the peripheral branches of the plexus. The posterior (green) and anterior (yellow) divisions of the lumbar plexus are shown in the diagram.

The lumbar plexus supplies the anterolateral abdominal wall, external genitals, and part of the lower limbs.



We will talk about the largest nerve arising from the lumbar plexus which is the femoral nerve.

The femoral nerve is distributed to the flexor muscles of hip joint and extensor muscles of knee joint, and to skin over anterior and medial aspect of thigh and medial side of leg and foot (like quadriceps, Sartorius, and others).

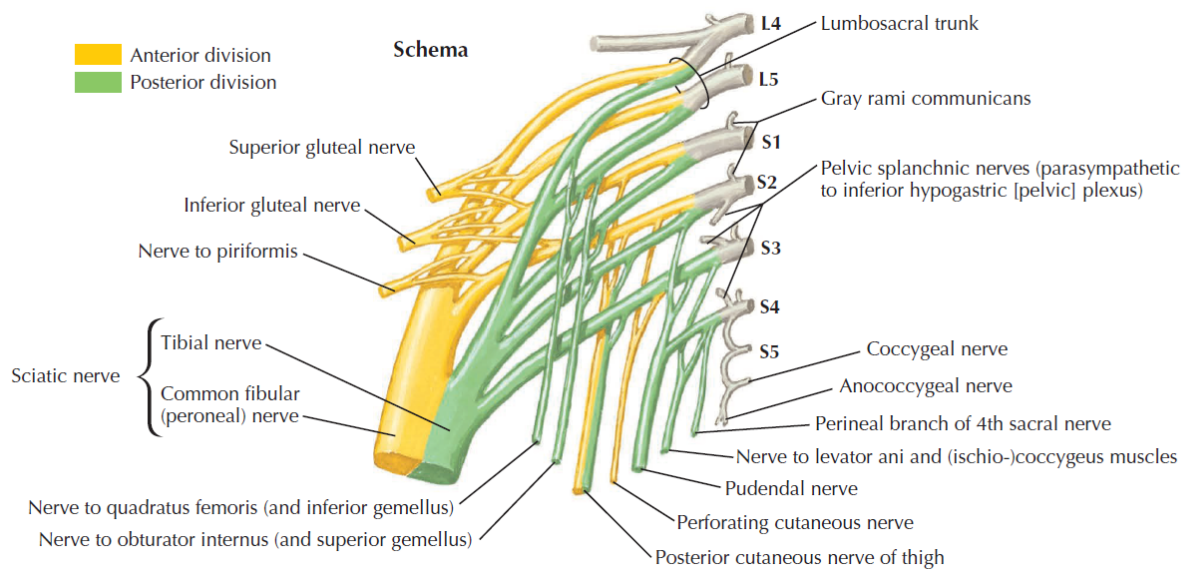


Sacral plexus:

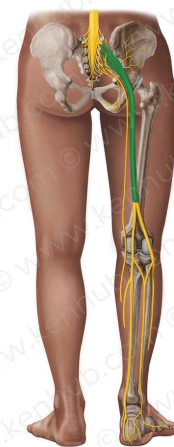The anterior rami of spinal nerves L4–L5 and S1–S4 form the roots of the sacral plexus. This plexus is situated largely anterior to the sacrum. The sacral plexus supplies the buttocks, perineum, and lower limbs. The largest nerve in the body—the sciatic nerve—arises from the sacral plexus.

The sciatic nerve which takes origin of the terminal branches of the lumbar L4 and L5 and the upper parts of the sacral S1, S2, and S3. It's going to supply muscles of the back of the thigh, this group of muscles is called hamstring muscles and it's going to supply muscles below the knee. So it's a major nerve supply of the lower limb and it's the largest nerve in the body.

The roots (anterior rami) of spinal nerves S4–S5 and the coccygeal nerves form a small coccygeal plexus. From this plexus arises the anococcygeal nerves, which supply a small area of skin in the coccygeal region.



The sciatic nerve which takes origin of the terminal branches of the lumbar L4 and L5 and the upper parts of the sacral S1, S2, and S3 (see the figure below). It's going to supply muscles of the back of the thigh (hamstring muscles) and it's going to supply muscles below the knee. Actually it contains two nerves—tibial and common fibular—bound together by common sheath of connective tissue.



Arteries of Spinal Cord and Nerve Roots:

Spinal cord is made of nervous tissue and nervous tissue can't tolerate anoxia, or lack of blood supply and oxygen. Therefore, several arteries go along the depressions on the external surface of the spinal cord to supply it. Vascular perfusions to the spinal cord are supplied by three longitudinally running vessels and several segmental branches. The longitudinally running vessels are the anterior spinal artery and two posterior spinal arteries. The posterior spinal arteries originate in the cranial cavity as branches of either the vertebral artery or PICA. These arteries descend along the length of the posterior spinal cord on the posterolateral sulcus. The single anterior spinal artery originates within the cranial cavity from the union of two contributing branches from the vertebral arteries. The anterior spinal artery descends along the length of the anterior spinal cord on the anterior median fissure.

Reinforcing vascular supply to these longitudinally running vessels is provided by segmental medullary arteries.

In the case of the brain, you can hear that there is an infarction of the brain because each are of the brain has specific artery that supplies it, if it's blocked then the areas will die. In case of the spinal cord, you don't hear about infarction of the spinal cord.

Note: anoxia is an extreme form of hypoxia. Hypoxia occurs when the body or one part of a person's body, such as the brain, can only obtain a reduced amount of oxygen. Anoxia occurs when the body does not get any oxygen.

